

Endophthalmitis

is an infection inside the eye that can either be acute or chronic, meaning that it can develop very rapidly which is most common, or develop slowly and persist for long periods of time

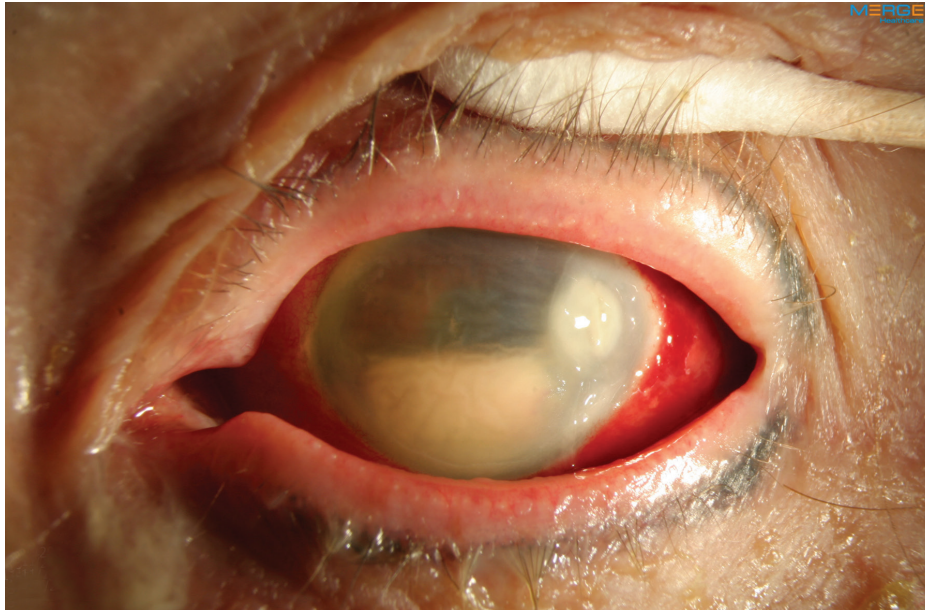


Figure 1
Hypopyon is an accumulation of white blood cells in the anterior chamber of the eye and corneal infiltrate associated with infectious endophthalmitis.

Causes: Acute cases of endophthalmitis are caused by gram-positive (or less frequently gram-negative) bacteria and are most often seen within 6 weeks after surgery or trauma to the eye.

Chronic cases that occur outside of the 6-week window are often related to a previous surgery and are commonly caused by slowly progressive infections such as *Propionibacterium acnes* or fungus.

Finally, systemic infections can spread to the eye causing endogenous endophthalmitis. This is often associated with systemic fungal or gram-negative bacterial infections. Patients who are debilitated, septicemic (bacteria in the bloodstream), and who have weakened immune systems are particularly susceptible, especially after surgical procedures.

Risk Factors: Loss of vitreous gel (also referred to as **vitreous humor**), disrupted **posterior capsule**, poor wound closure, and prolonged surgery are risk factors for developing endophthalmitis. The incidence following penetrating trauma is 4-13% and may be as high as 30% after injuries in rural settings.

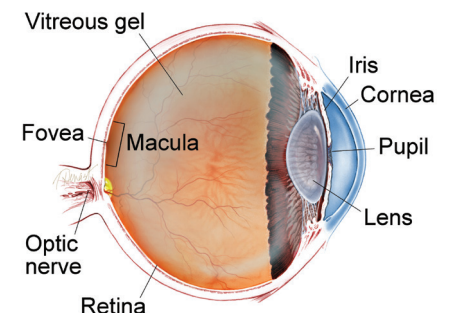
SIGNS AND SYMPTOMS

Endophthalmitis causes the white of the eye to be inflamed. There may be a white or yellow discharge on or inside the eyelid, and the cornea may show a white cloudiness. There may also be a layer of white cells (**hypopyon**) present within the anterior chamber of the eye between the iris and the cornea. (Figure 1) Endophthalmitis is usually a very serious problem and prompt examination by an ophthalmologist is essential to make an appropriate diagnosis and initiate treatment.

Other symptoms include:

- Eye pain and redness
- Decreased vision
- Trouble looking at bright lights (photophobia), usually sudden onset ●

WHAT IS THE RETINA?



THE RETINA is a thin layer of light-sensitive nerve tissue that lines the back of the eye (or vitreous) cavity. When light enters the eye, it passes through the iris to the retina where images are focused and converted to electrical impulses that are carried by the optic nerve to the brain resulting in sight.

Endophthalmitis

continued from previous page

Risk factors for endophthalmitis after trauma include:

- Retained intraocular foreign body (having foreign material remain in your eye following an injury)
- Delayed surgery (longer than 24 hours) to repair a full-thickness laceration
- Rural setting (soil contamination)
- Damage to the lens during trauma

Diagnostic Testing: To determine what organism has caused the infection, a biopsy of the fluid within your eye needs to be obtained. This fluid is then sent to the laboratory for a determination and to decide on the best treatment.

Treatment: In acute cases, treating endophthalmitis is an emergency and needs to be performed as soon as possible. The procedure performed will depend on your vision. If your vision is very poor, you will need to undergo an emergency surgery called a **vitrectomy** to remove the infectious debris from your eye and to inject antibiotics or antifungal agents directly inside your eye. Cases with better vision may only require an injection of antibiotics or antifungal agents in the office. In rare cases, only antibiotic eye drops are required.

Prognosis: The prognosis depends on the cause, duration, and type of organism that caused the infection. Outcomes are often less favorable for traumatic cases involving gram negative organisms. Some cases involving gram positive bacterial infections after **cataract** surgery fare better. Eyes with endophthalmitis often require frequent examinations to obtain the best outcomes. ●

Clinical Terms *(appearing green within fact sheet text)*

Cataract: A clouding of the eye's lens causing a decrease in vision. Cataracts are the most common cause of vision loss for those over the age of 40.

Hypopyon: Accumulation of white blood cells in the anterior chamber of the eye.

Posterior capsule : A thin membrane that comprises the back surface of the eye's lens.

Vitrectomy surgery: A procedure undertaken by a specialist where the vitreous gel that fills the eye cavity is removed to provide better access to the retina. This allows for a variety of repairs, including the removal of scar tissue, laser repair of retinal detachments and treatment of macular holes. Once surgery is complete, saline, a gas bubble or silicone oil may be injected into the vitreous cavity to help hold the retina in position while the eye heals.

There are different types of vitrectomy:

- Pars plana vitrectomy is performed by retina specialists to address diseases of the 'posterior' (back) segment of the eye cavity, also referred to as the pars plana.
- Anterior vitrectomy is performed by ophthalmologists or retina specialists to address leakage of vitreous gel into the front (anterior) chamber of the eye.

Vitreous or vitreous humor: The "gel" that fills the inside of the eye or vitreous cavity.