

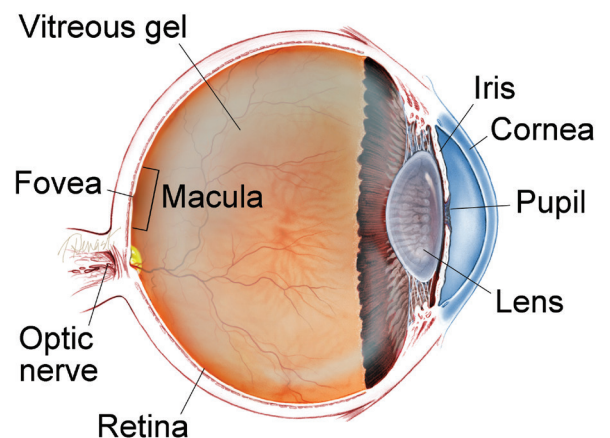
Epiretinal Membranes (ERMs), also commonly known as *cellophane maculopathy* or *macular puckers*, are avascular (having few or no blood vessels), semi-translucent, fibrocellular membranes that form on the inner surface of the retina. They most commonly cause minimal symptoms and can be simply observed, but in some cases they can result in painless loss of vision and metamorphopsia (visual distortion). Generally, ERMs are most symptomatic when affecting the macula, which is the central portion of the retina that helps us to distinguish fine detail used for reading and recognizing faces.

Causes: The cause of ERMs is due to a defect in the surface layer of the retina where a type of cell, called glial cells, can migrate through and start to grow in a membranous sheet on the retinal surface. This membrane can appear like cellophane and over time may contract and cause traction (or pulling) and puckering of the retina, leading to decreased vision and metamorphopsia.

The most common cause of macular pucker is an age-related condition called *posterior vitreous detachment* (PVD), where the vitreous gel that fills the eye separates from the retina, causing symptoms of floaters and flashes. If there is no specific cause apart from the PVD, the ERM is called *idiopathic* (of unknown origin).

continued next page

WHAT IS THE RETINA?



THE RETINA is a thin layer of light-sensitive nerve tissue that lines the back of the eye (or vitreous) cavity. When light enters the eye, it passes through the iris to the retina where images are focused and converted to electrical impulses that are carried by the optic nerve to the brain resulting in sight.

Epiretinal Membranes *continued from previous page*

ERMs can be associated with a number of ocular conditions such as prior retinal tears or detachment, retinal vascular diseases such as diabetic retinopathy or venous occlusive disease; they can also be post-traumatic, occurring following ocular surgery, or be associated with intraocular (inside the eye) inflammation.

Risk Factors: The risk of developing an ERM increases with age, and persons with predisposing ocular conditions may develop ERM at an earlier age. The most common association, however, is PVD. Studies have shown that 2% of patients over age 50 and 20% over age 75 have evidence of ERMs, although most do not need treatment. Both sexes are equally affected. In about 10% to 20% of cases, both eyes have ERMs, but they can be of varying degrees of severity.

Diagnostic Testing: Most ERM cases can be diagnosed by an eye care provider during a routine clinical exam. **Ocular Coherence Tomography (OCT)** is an important imaging method used to assess the severity of the ERM (*Figure 1*). Sometimes, additional testing such as **fluorescein angiography** is used to determine if other underlying retinal problems have caused the ERM.

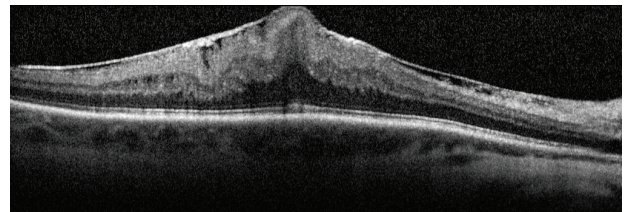


Figure 1
Epiretinal Membrane (OCT)
Image courtesy of John Thompson, MD

Treatment and Prognosis: Since most ERMs are fairly stable after an initial period of growth, they can simply be monitored as long as they are not affecting vision significantly. In rare circumstances, the membrane will spontaneously release from the retina, relieving the traction and clearing up the vision. However, if an exam shows progression and/or functional worsening in vision, surgical intervention maybe recommended.

continued next page

Epiretinal Membranes *continued from previous page*

There are no eye drops, medications or nutritional supplements to treat ERMs. A surgical procedure called **vitrectomy** is the only option in eyes that require treatment. With vitrectomy, small incisions are placed in the white part of the eye, and the vitreous gel filling the inside of the eye is replaced with saline. This allows access to the surface of the retina where the ERM can be removed with delicate forceps, thereby allowing the macula to relax and become less wrinkled. Visual recovery is slow and most eyes experience improvement within 3 months but it may take a year to attain maximal visual acuity improvement.

The risk of complications with vitrectomy is small, with about 1 in 100 patients developing retinal detachment and 1 in 2000 developing infection after surgery. Patients who still have their natural lens will develop increased progression of a cataract in the surgical eye following surgery.

continued next page

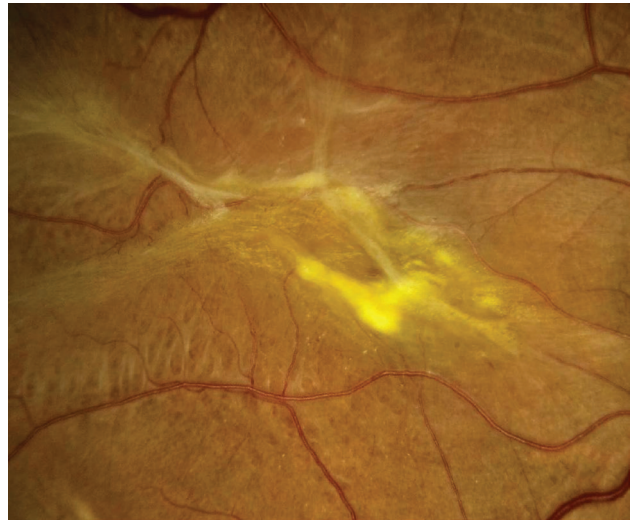

Figure 2
Epiretinal Membrane

Sharon Fekrat, MD, FACS, Duke University Eye Center. Retina Image Bank 2012; Image 1437. ©American Society of Retina Specialists

Epiretinal Membranes *continued from previous page*

Factors affecting visual outcome include:

- Length of time the ERM has been present
- The degree of traction (or pulling)
- The cause of the ERM (Idiopathic ERMs have a better prognosis than eyes with prior retinal detachment or retinal vascular diseases)

Surgery for ERM has a good success rate, and most patients experience improved visual acuity and decreased **metamorphopsia** following vitrectomy. ●

SYMPTOMS

Most patients with ERMs have no symptoms; their ERMs are found incidentally on dilated retinal exam or on retinal imaging such as with ocular coherence tomography (OCT). In such cases, patients typically have normal or near-normal vision. However, ERMs can slowly progress, leading to a vague visual distortion that can be perceived better by closing the non- or less-affected eye.

Patients may notice metamorphopsia, a symptom that causes visual distortion in which shapes that are normally straight, like window blinds or a door frame, looking “wavy” or “crooked,” especially when compared to the other eye. In advanced cases, this can lead to severely decreased vision. Less commonly, ERMs may also be associated with double vision, light sensitivity or images looking larger or smaller than they actually are. ●

continued next page

Epiretinal Membranes *continued from previous page*

Clinical Terms (*appearing green within fact sheet text*)

Fluorescein angiography (FA): An imaging technique where a yellow dye called *sodium fluorescein* is injected into a vein in the arm, allowing a special camera to record circulation in the retina and *choroid* in the back of the eye. This test can be very useful in diagnosing a number of retinal disorders.

Metamorphopsia: A symptom causing visual distortion that makes things that are normally straight, like window blinds or a door frame, appear wavy or crooked.

Optical coherence tomography (OCT): A non-invasive imaging technique that uses light to create a 3-dimensional image of your eye for physician evaluation.

Pars plana vitrectomy surgery (also called vitrectomy): A treatment option that involves removal of the vitreous gel. This allows the release of vitreous attachment and alleviates traction (or pulling) on the retina.

THANK YOU TO THE RETINA HEALTH SERIES AUTHORS

Sophie J. Bakri, MD
Audina Berrocal, MD
Antonio Capone, Jr., MD
Netan Choudhry, MD, FRCS-C
Thomas Ciulla, MD, MBA
Pravin U. Dugel, MD
Geoffrey G. Emerson, MD, PhD
K. Bailey Freund, MD
Roger A. Goldberg, MD, MBA
Darin R. Goldman, MD
Dilraj Grewal, MD
Larry Halperin, MD
Vi S. Hau, MD, PhD
Suber S. Huang, MD, MBA
G. Baker Hubbard, MD
Mark S. Humayun, MD, PhD
Talia R. Kaden, MD
Peter K. Kaiser, MD
M. Ali Khan, MD
Anat Loewenstein, MD
Mathew J. MacCumber, MD, PhD
Maya Maloney, MD
Timothy G. Murray, MD, MBA
Hossein Nazari, MD
Oded Ohana, MD, MBA
George Parlitsis, MD
Jonathan L. Prenner, MD
Gilad Rabina, MD
Carl D. Regillo, MD, FACS
Naryan Sabherwal, MD
Sherveen Salek, MD
Andrew P. Schachat, MD
Michael Seider, MD
Janet S. Sunness, MD
Eduardo Uchiyama, MD
Allen Z. Verne, MD
Christina Y. Weng, MD, MBA
Yoshihiro Yonekawa, MD

EDITOR

John T. Thompson, MD

MEDICAL ILLUSTRATOR

Tim Hengst