

Intraocular Lens Dislocation Cataract surgery is one of the most common and successful surgical procedures performed today. Over the past decade, the risk of severe complications has decreased with advances in surgical instruments and techniques. In the procedure, the **cataract** (cloudy lens) is removed, and a clear intraocular (in-the-eye) lens is placed. Rare complications include intraocular lens (IOL) dislocation, where the lens moves out of place.

Causes: During most cataract surgery procedures, the IOL is placed inside the capsular bag, a sack-like structure in the eye that previously contained the cloudy lens. In some situations, this extremely thin capsular bag or the fibers that hold it in place rupture and the IOL support is compromised.

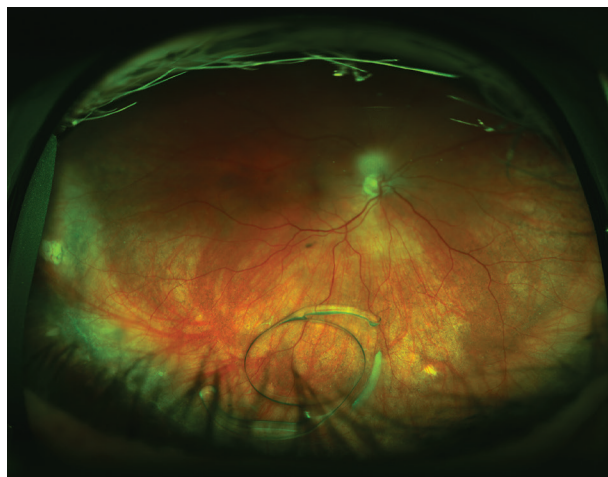

Figure 1
Dislocated intraocular lens in vitreous cavity.
Photo courtesy of Larry Halperin, MD

Dislocation of the IOL can occur days to years after surgery and can be a result of factors during the original surgery, trauma to the eye, or diseases that affect the stability of the capsular bag.

Risk Factors:

- Trauma
- Prior vitreoretinal surgery
- **Pseudoexfoliation syndrome** (a condition that causes instability of the capsular bag where the IOL is placed)
- Certain connective tissue disorders
- Inflammation in the eye (uveitis)

Diagnostic Testing: Your retina specialist will perform a detailed eye exam, including a careful examination of the **peripheral retina**.

The dislocated IOL is sometimes photographed to document the extent of the problem. When a clear view of the retina cannot be obtained directly, an ultrasound of the eye can be helpful.

SYMPTOMS

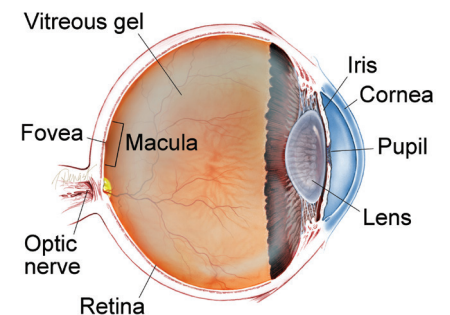
The most common symptom of a dislocated IOL is a change in vision. The degree to which vision is affected will depend on the severity of the dislocation.

This can appear as:

- Blurring
- Double vision
- Seeing the edge of the lens implant

IOL dislocation can also lead to other complications such as **retinal detachment**, bleeding, intraocular inflammation, **macular edema**, **glaucoma**, and **corneal edema**.

WHAT IS THE RETINA?



THE RETINA is a thin layer of light-sensitive nerve tissue that lines the back of the eye (or vitreous) cavity. When light enters the eye, it passes through the iris to the retina where images are focused and converted to electrical impulses that are carried by the optic nerve to the brain resulting in sight.

continued next page

Intraocular Lens Dislocation

continued from previous page

Treatment and Prognosis: Based on the characteristics of the IOL dislocation, there are several different approaches to repairing this issue.

In cases where the IOL dislocation is minimal and does not have a large impact on vision, your doctor may not recommend any treatment at all.

When vision is affected and the patient is experiencing symptoms, surgery becomes necessary. In this surgical procedure, the vitreous gel that fills the eye's rear cavity is removed (**vitrectomy**) to prevent pulling on the retina while the IOL is being manipulated.

Techniques for repairing a dislocated IOL fall into 2 categories. Your doctor will choose the one that is most appropriate based on your IOL type and the anatomy of your eye:

- IOL rescue/reposition: The dislocated IOL is preserved and repositioned in a more stable location. The possibility of using the existing lens is based on many factors including the style and condition of the IOL.
- IOL exchange: The IOL is removed and a new IOL is inserted.

Potential complications of the procedure include retinal detachment, uveitis (inflammation inside the eye), infection, glaucoma, bleeding, and re-dislocation of the IOL.

With prompt and careful management, most patients with IOL dislocation have a good visual outcome following a corrective procedure. ●

Clinical Terms *(appearing green within fact sheet text)*

Cataract: A clouding of the eye's lens causing a decrease in vision. Cataracts are the most common cause of vision loss for those over the age of 40.

Corneal edema: Swelling of the cornea that may be caused by eye surgery, trauma, infection or ocular (eye) disease.

Glaucoma: A condition where fluid buildup in the eye causes an increase in eye pressure that damages the optic nerve.

Macular edema: The term used for swelling in the macula in eyes, or the center part of the retina which is responsible for providing the sharp, straight-ahead vision used for reading and recognizing faces as well as color vision.

Peripheral retina: The area outside of the central retina. This includes the equatorial and anterior retina.

Pseudoexfoliation syndrome: An age-related disease that causes whitish-grey protein deposits to form on the eye's lens, iris, ciliary epithelium, corneal endothelium and trabecular meshwork.

Retinal detachment: A condition where the retina separates from the back of the eye wall. This may be caused by vitreous fluid leaking through a retinal tear or hole and collecting under the retina, causing it to separate from the tissue around it.

Vitrectomy surgery: A procedure undertaken by a specialist where the vitreous gel that fills the eye cavity is removed to provide better access to the retina. This allows for a variety of repairs, including the removal of scar tissue, laser repair of retinal detachments and treatment of macular holes. Once surgery is complete, saline, a gas bubble or silicone oil may be injected into the vitreous cavity to help hold the retina in position while the eye heals.

There are different types of vitrectomy:

- Pars plana vitrectomy is performed by retina specialists to address diseases of the 'posterior' (back) segment of the eye cavity, also referred to as the pars plana.
- Anterior vitrectomy is performed by ophthalmologists or retina specialists to address leakage of vitreous gel into the front (anterior) chamber of the eye.

THANK YOU TO THE RETINA HEALTH SERIES AUTHORS

Sophie J. Bakri, MD
Audina Berrocal, MD
Antonio Capone, Jr., MD
Netan Choudhry, MD, FRCS-C
Thomas Ciulla, MD, MBA
Pravin U. Dugel, MD
Geoffrey G. Emerson, MD, PhD
Roger A. Goldberg, MD, MBA
Darin R. Goldman, MD
Dilraj Grewal, MD
Larry Halperin, MD
Vincent S. Hau, MD, PhD
Suber S. Huang, MD, MBA
Mark S. Humayun, MD, PhD
Peter K. Kaiser, MD
M. Ali Khan, MD
Anat Loewenstein, MD
Mathew J. MacCumber, MD, PhD
Maya Maloney, MD
Hossein Nazari, MD
Oded Ohana, MD, MBA
George Parlitsis, MD
Jonathan L. Prenner, MD
Gilad Rabina, MD
Carl D. Regillo, MD, FACS
Andrew P. Schachat, MD
Michael Seider, MD
Eduardo Uchiyama, MD
Allen Z. Verne, MD
Yoshihiro Yonekawa, MD

EDITOR

John T. Thompson, MD

MEDICAL ILLUSTRATOR

Tim Hengst