

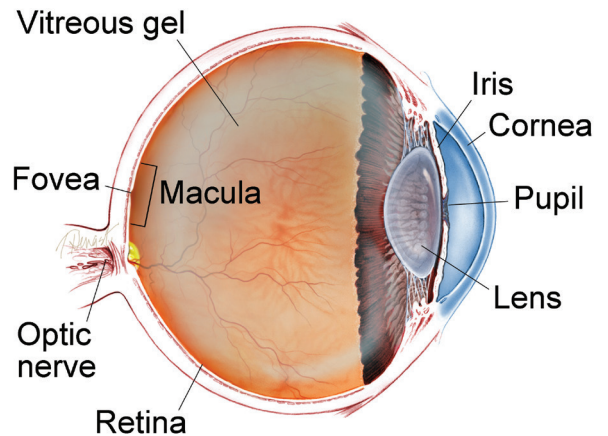


Age-Related Macular Degeneration (AMD) is a deterioration of the retina and **choroid** that leads to a substantial loss in visual acuity (sharpness of vision). AMD is the leading cause of significant visual acuity loss in people over age 50 in developed countries.

Causes: The exact cause of AMD is unknown, but the condition develops as the eye ages. There are 2 types of AMD: non-neovascular or *dry* AMD; and neovascular or *wet* AMD.

In early stages of dry AMD, the hallmark is *drusen*—pale yellow lesions formed beneath the retina (*Figure 1A*). Drusen are usually harmless, but as they accumulate, dry AMD can progress. Atrophic areas (areas of atrophy or wasting) in the retina also may develop; if the atrophic area is significant and with sharp borders, it is termed geographic atrophy (GA) (*Figure 1B*).

WHAT IS THE RETINA?



THE RETINA is a thin layer of light-sensitive nerve tissue that lines the back of the eye (or vitreous) cavity. When light enters the eye, it passes through the iris to the retina where images are focused and converted to electrical impulses that are carried by the optic nerve to the brain resulting in sight.

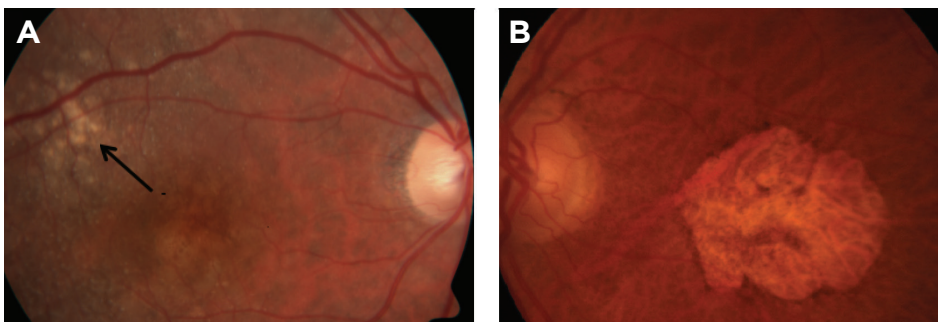


Figure 1

Dry AMD.

A. Drusen (indicated by arrow).

B. Geographic atrophy

Photo courtesy

Anat Loewenstein, MD

continued next page

Age-Related Macular Degeneration *continued from previous page*

GA is the advanced form of dry AMD, which may be associated with loss of central vision.

In wet AMD, there is a sudden or gradual decrease in visual acuity, blind spots in the center of vision, and distortion of straight lines. The hallmark of wet AMD is **choroidal neovascularization** (CNV) (*Figure 2*).

CNV occurs when abnormal blood vessels grow beneath the retina; these can bleed or leak and cause a distortion of the retina's structure. Ultimately, the CNV can turn into a **disciform scar** that replaces the normal architecture of the outer retina and leads to permanent loss of central vision.

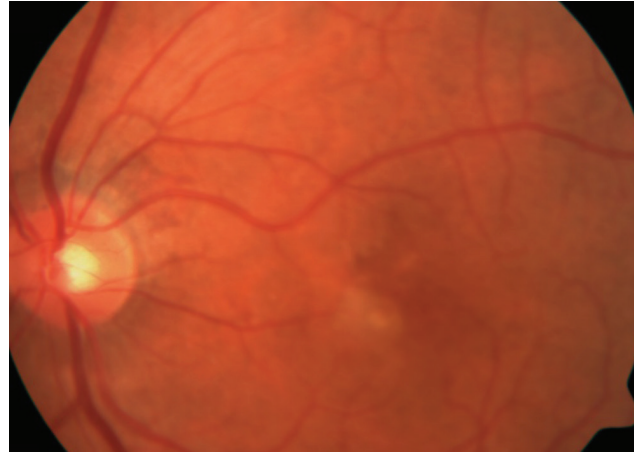


Figure 2

Wet AMD. Choroidal neovascularization (indicated by arrow).

Photo courtesy Anat Loewenstein, MD

Risk Factors:

- Age—the strongest risk factor
- Caucasian race
- Family history of AMD
- Cigarette smoking

Possible risk factors:

- Female gender
- Lower level of education
- Light iris color
- Far-sightedness
- Cardiovascular (heart) disease
- High blood pressure
- High cholesterol
- Sunlight exposure
- Low dietary fish intake
- Higher body mass index (BMI)
- Having a diet low in lutein and zeaxanthin/antioxidants

continued next page

Age-Related Macular Degeneration *continued from previous page*

Diagnostic Testing: Disease features related to AMD may be found in the retina and in the layers beneath it. According to these abnormal findings, AMD is classified as dry or wet.

An AMD diagnosis is made by a clinical examination with a **slit lamp** and by using several types of imaging, including:

- **Fluorescein angiography** (FA)
- **Indocyanine green angiography** (ICGA)
- **Optical coherence tomography** (OCT)
- **Optical coherence tomography angiography** (OCTA)

Treatment and Prognosis: Wet-AMD treatment has been revolutionized in recent years after the discovery of *vascular endothelial growth factor* (VEGF), a family of compounds in the body. VEGF regulates the growth of abnormal new blood vessels in the eye—known as *neovascularization*—that can lead to wet AMD.

Anti-VEGF drugs have been developed to help stop neovascularization and preserve vision for AMD patients. There are currently 5 different anti-VEGF drugs:

- Avastin® (bevacizumab)
- Lucentis® (ranibizumab)
- Eylea® (aflibercept)
- Beovu® (brolucizumab)
- Vabysmo® (faricimab)

There is also an extended release device (Susvimo®) that can be implanted in the operating room and refilled in the office every 24 weeks with a concentrated form of Lucentis.

Wet AMD cannot be cured, but its progression may be blocked with the use of *intravitreal* (in-the-eye) anti-VEGF injections. These

SYMPTOMS

In early stages, AMD may have no symptoms at all. When the disease progresses, the symptoms are:

- Distortion (warping) of straight lines
- A decrease in the intensity or brightness of colors

As the macular degeneration progresses, AMD symptoms include:

- A gradual or sudden loss of central vision, or
- Dark, blurry areas in the center of vision ●

continued next page

Age-Related Macular Degeneration *continued from previous page*

injections may preserve, and even recover, vision. Local anesthetic eye drops are given before the injections to numb the eye and minimize discomfort.

There are 3 anti-VEGF treatment regimens commonly used for Avastin, Lucentis, Eylea, Beovu and Vabysmo. The best option is chosen in consultation with your retina specialist.

1. *Pro re nata* (PRN) or “treat and observe”—patients are treated with three initial monthly injections, followed by treatment as needed.
2. “Treat and extend”—after 3 initial monthly injections, the time between treatments is gradually increased as tolerated. Some eyes will continue to require monthly injections, but others can be treated less often as long as the wet AMD is controlled.
3. Monthly injections.

Before the first anti-VEGF drugs were introduced, wet-AMD patients were treated with **laser photocoagulation** or **photodynamic therapy** (PDT).

Anti-VEGF drugs have greatly improved wet-AMD treatment since 2005; patients today have a much better chance of maintaining their central vision so they can read, drive, recognize faces, and live normal lives.

No current treatment can prevent visual loss for patients with GA (the advanced form of dry AMD). However, the Age-Related Eye Disease Studies (AREDS), conducted by the National Eye Institute, have found that a nutritional supplement formula (AREDS-2 supplement) may delay and prevent intermediate dry AMD from moving to the advanced form.

The AREDS-2 supplement formula, which is widely available over the counter, contains specific doses of vitamins and minerals used in the AREDS-2 Study:

- Vitamin C
- Vitamin E
- Zinc
- Lutein
- Zeaxanthin

Although patients with either form of AMD can experience a progressive decrease in visual acuity, they will almost never be completely blind. ●

continued next page

Age-Related Macular Degeneration *continued from previous page*

Clinical Terms

(appearing green within fact sheet text)

Choroid (pronounced CORE oid): The layer of blood vessels and connective tissue between the retina and the white of the eye, also known as the *sclera*.

Choroidal Neovascularization (CNV): Growth of abnormal new blood vessels in the choroid layer of the eye that grow under the retina and macula and disrupt vision.

Disciform scar: A scar that develops in the macula area of the retina resulting from leakage and bleeding from abnormal blood vessels (neovascularization) in the eye.

Fluorescein angiography (FA): An imaging technique where a yellow dye called *sodium fluorescein* is injected into a vein in the arm, allowing a special camera to record circulation in the retina and *choroid* in the back of the eye. This test can be very useful in diagnosing a number of retinal disorders.

Indocyanine green angiography (ICGA): A diagnostic procedure that uses a green dye to illuminate blood flow in the choroid, which is a layer of blood vessels located between the white of the eye (*sclera*) and the retina that supplies nutrients to the inner eye.

Laser photocoagulation: A surgical technique that uses a highly targeted laser light to seal blood vessels and coagulate (clot) tissue.

Optical coherence tomography (OCT): A non-invasive imaging technique that uses light to create a 3-dimensional image of your eye for physician evaluation.

continued next page

Age-Related Macular Degeneration *continued from previous page***Clinical Terms***(appearing green within fact sheet text)*

Optical coherence tomography angiography (OCTA): A noninvasive imaging technique that uses light to image the blood vessels in different layers of the retina and choroid.

Photodynamic therapy (PDT): A treatment for macular degeneration in which a light-activated medicine (verteporfin) is injected into the bloodstream followed by application of a cold laser which targets abnormal blood vessels growing in the macula at the center of the retina.

Slit lamp: An instrument that combines a high-intensity light source with a microscope to examine the external and internal structures of the eye, including the optic nerve and retina.

**THANK YOU TO THE
RETINA HEALTH SERIES
AUTHORS**

Sophie J. Bakri, MD
Audina Berrocal, MD
Antonio Capone, Jr., MD
Netan Choudhry, MD, FRCS-C
Thomas Ciulla, MD, MBA
Pravin U. Dugel, MD
Geoffrey G. Emerson, MD, PhD
K. Bailey Freund, MD
Roger A. Goldberg, MD, MBA
Darin R. Goldman, MD
Dilraj Grewal, MD
Larry Halperin, MD
Vi S. Hau, MD, PhD
Suber S. Huang, MD, MBA
G. Baker Hubbard, MD
Mark S. Humayun, MD, PhD
Talia R. Kaden, MD
Peter K. Kaiser, MD
M. Ali Khan, MD
Ivana K. Kim, MD
Anat Loewenstein, MD
Mathew J. MacCumber, MD, PhD
Maya Maloney, MD
Timothy G. Murray, MD, MBA
Hossein Nazari, MD
Oded Ohana, MD, MBA
Jonathan L. Prenner, MD
Gilad Rabina, MD
Carl D. Regillo, MD, FACS
Naryan Sabherwal, MD
Sherveen Salek, MD
Andrew P. Schachat, MD
Adrienne W. Scott, MD
Michael Seider, MD
Janet S. Sunness, MD
Eduardo Uchiyama, MD
Allen Z. Verne, MD
Christina Y. Weng, MD, MBA
Yoshihiro Yonekawa, MD

EDITOR

John T. Thompson, MD

MEDICAL ILLUSTRATOR

Tim Hengst