



Presumed Ocular Histoplasmosis Syndrome (POHS) causes atrophy (wasting) around the optic nerve and multiple scars, called *histo spots*, in the **choroid**. These symptoms are accompanied by new blood vessel growth (**neovascularization**) that starts adjacent to a histo spot.

Causes: Histoplasmosis is a disease caused by *Histoplasma capsulatum* (*H. capsulatum*), a soil fungus prevalent in certain parts of the American continent, in particular the Ohio and Mississippi River valleys. POHS has also been found to be prevalent in the same areas where 60% of the adult population is estimated to react positively to histoplasmin skin testing and 2% show the typical signs of focal chorioretinal scars in the eye.

Consequently, it is thought that *H. capsulatum* enters the eye from the bloodstream, invading the choroidal vessels and ultimately causing scarring. However, it has never been directly proven that *H. capsulatum* causes POHS, hence the name *presumed* ocular histoplasmosis syndrome.

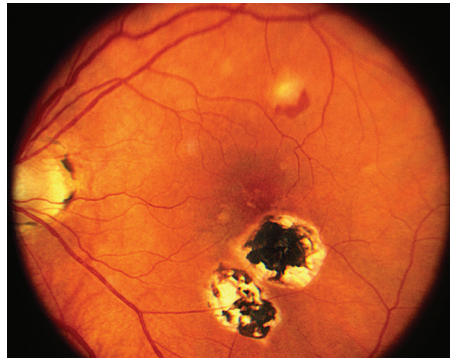


Figure 1
Color fundus photograph of the right eye of a patient with POHS shows typical punched out scars and peripapillary atrophy.

Henry Kaplan, MD. Presumed Ocular Histoplasmosis Syndrome.
Retina Image Bank 2013; Image 4951.
© the American Society of Retina Specialists.

Risk Factors: The vast majority of patients with POHS have no known history of systemic infection. One theory is that when childhood infection with *H. capsulatum* occurs, the fungus spreads through the bloodstream to the eye and choroid, where scars form and remain long after the systemic infection subsides.

The histoplasmosis infection usually does not cause symptoms throughout the body, so most people never realize they have histoplasmosis scars, or histo spots, in their retina. The scars can later lead to neovascularization in the **macula** resulting in visual loss. This occurs most frequently in the second to fifth decade of life. These patients may have a history of childhood exposure to chickens. This happens as often in males as in females and it is predominantly found in the Caucasian population.

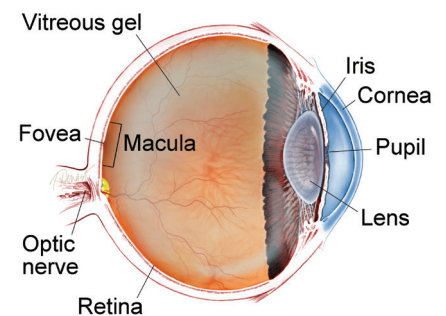
Diagnostic Testing: **Ocular coherence tomography (OCT)** and **fluorescein angiography (FA)** are performed to evaluate for neovascularization in patients who visit their doctor with symptoms of visual loss (*Figure 2*).

continued next page

SYMPTOMS

Histo spots (*Figure 1*) are considered the earliest stage of the disease. **Less than 5% of individuals with histo spots will develop neovascularization in the central macula (at the middle of the retina).** Because the histo spots themselves usually do not cause symptoms, patients typically do not develop symptoms until neovascularization grows in the central macula. Symptoms include painless progressive blurring of central vision and wavy vision (metamorphosia), which can be sudden or develop slowly. ●

WHAT IS THE RETINA?



THE RETINA is a thin layer of light-sensitive nerve tissue that lines the back of the eye (or vitreous) cavity. When light enters the eye, it passes through the iris to the retina where images are focused and converted to electrical impulses that are carried by the optic nerve to the brain resulting in sight.

Presumed Ocular Histoplasmosis Syndrome

continued from previous page

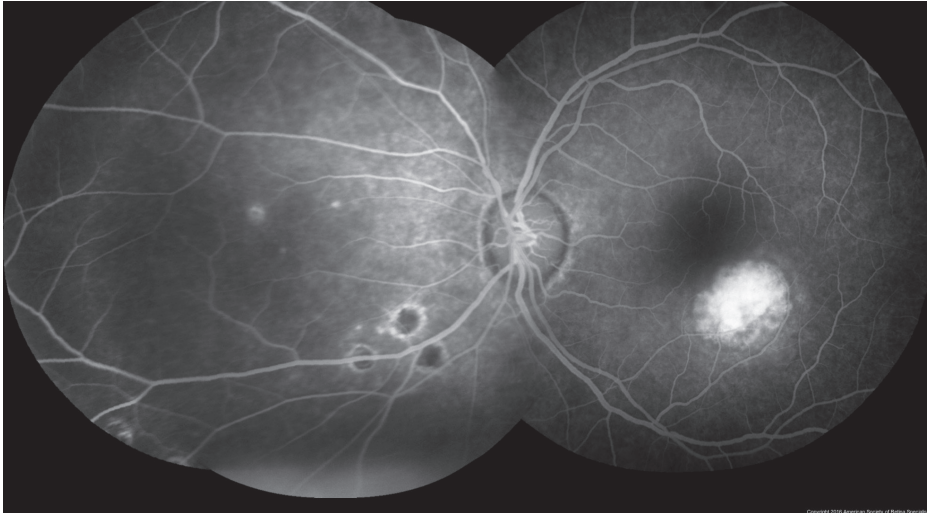


Figure 2

John S. King, MD. Presumed Ocular Histoplasmosis Syndrome. Retina Image Bank 2012; Image 421.
© the American Society of Retina Specialists.

Treatment and Prognosis: Treatment is generally required only when there is neovascularization. Given that *H. capsulatum* does not seem to play a direct role in the development of POHS, antifungal agents are not used to treat POHS. However, injections of medications that inhibit neovascularization are recommended. These medications include bevacizumab (Avastin[®]), ranibizumab (Lucentis[®]) and aflibercept (Eylea[®]).

Prior to injection, the eye is given an anesthetic drop or gel and is cleaned with povidone iodine; the injection generally causes minimal, if any, pain. Injections are initially administered monthly or less frequently until the neovascularization improves, as confirmed by OCT or FA. If neovascularization is treated early, before advanced scarring develops in the central macula, the prognosis for vision is generally good. ●

THANK YOU TO THE RETINA HEALTH SERIES AUTHORS

Sophie J. Bakri, MD
Audina Berrocal, MD
Antonio Capone, Jr., MD
Netan Choudhry, MD, FRCS-C
Thomas Ciulla, MD, MBA
Pravin U. Dugel, MD
Geoffrey G. Emerson, MD, PhD
K. Bailey Freund, MD
Roger A. Goldberg, MD, MBA
Darin R. Goldman, MD
Dilraj Grewal, MD
Larry Halperin, MD
Vi S. Hau, MD, PhD
Suber S. Huang, MD, MBA
G. Baker Hubbard, MD
Mark S. Humayun, MD, PhD
Talia R. Kaden, MD
Peter K. Kaiser, MD
M. Ali Khan, MD
Ivana K. Kim, MD
Anat Loewenstein, MD
Mathew J. MacCumber, MD, PhD
Maya Maloney, MD
Timothy G. Murray, MD, MBA
Hossein Nazari, MD
Oded Ohana, MD, MBA
Jonathan L. Prenner, MD
Gilad Rabina, MD
Carl D. Regillo, MD, FACS
Naryan Sabherwal, MD
Sherveen Salek, MD
Andrew P. Schachat, MD
Adrienne W. Scott, MD
Michael Seider, MD
Janet S. Sunness, MD
Eduardo Uchiyama, MD
Allen Z. Verne, MD
Christina Y. Weng, MD, MBA
Yoshihiro Yonekawa, MD

EDITOR

John T. Thompson, MD

MEDICAL ILLUSTRATOR

Tim Hengst

Clinical Terms *(appearing green within fact sheet text)*

Choroid (pronounced CORE oid): The layer of blood vessels and connective tissue between the retina and the white of the eye, also known as the sclera.

Fluorescein angiography (FA): An imaging technique where a yellow dye called sodium fluorescein is injected into a vein in the arm, allowing a special camera to record circulation in the retina and choroid in the back of the eye. This test can be very useful in diagnosing a number of retinal disorders.

Macula: A small area at the center of the retina where light is sharply focused to produce the detailed color vision needed for tasks such as reading and driving.

Neovascularization: Excessive growth of new blood vessels on abnormal tissue as a result of oxygen deprivation that can cause vision loss.

Optical coherence tomography (OCT): A non-invasive imaging technique that uses light to create a 3-dimensional image of your eye for physician evaluation.