



Acquired Vitelliform Lesions

Adult-onset vitelliform maculopathy is a retinal disease characterized by round, yellowish deposits (acquired vitelliform lesions, or AVLs) found beneath the central retina or macula (Figure 1). Other names used for these findings include *adult pattern dystrophy* and *adult-onset foveomacular pigment epithelial dystrophy*.

Symptoms: Patients with adult-onset vitelliform maculopathy may notice decreased or distorted vision. In milder cases, an ophthalmologist may notice the vitelliform deposits before they have caused visual symptoms.

Causes and Risk Factors:

- AVLs usually occur in adults in their 40s and 50s. This is in contrast to the vitelliform lesions occurring in best vitelliform macular dystrophy, an inherited disorder, which usually occur earlier in life.
- AVLs are often the only abnormality seen in the eye, although they can also be associated with other yellow deposits called *drusen* that are considered a finding of age-related macular degeneration (AMD). (Figure 1)
- AVLs are located in the subretinal space, which is beneath the retina, but above a layer of pigmented cells known as the **retinal pigment epithelium** (RPE). (Figure 2)
- The deposits are thought to be primarily composed of degenerating parts of **photoreceptors**, the cells that make up the outer retina and are important for vision.

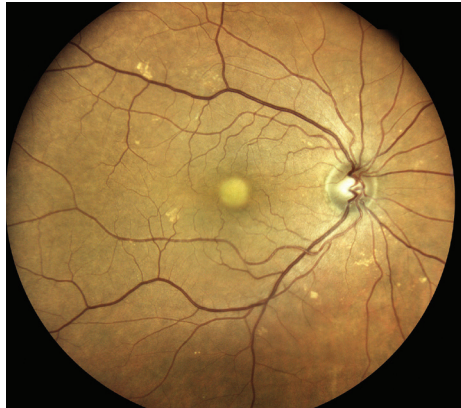


Figure 1. A vitelliform lesion under the fovea in a right eye. The vision in this person is 20/60 with glasses. Smaller scattered yellow spots known as drusen also are visible. (Photo courtesy of K. Bailey Freund, MD)

WHAT IS THE RETINA?

THE RETINA is a thin layer of light-sensitive nerve tissue that lines the back of the eye (or vitreous) cavity. When light enters the eye, it passes through the iris to the retina where images are focused and converted to electrical impulses that are carried by the optic nerve to the brain resulting in sight.

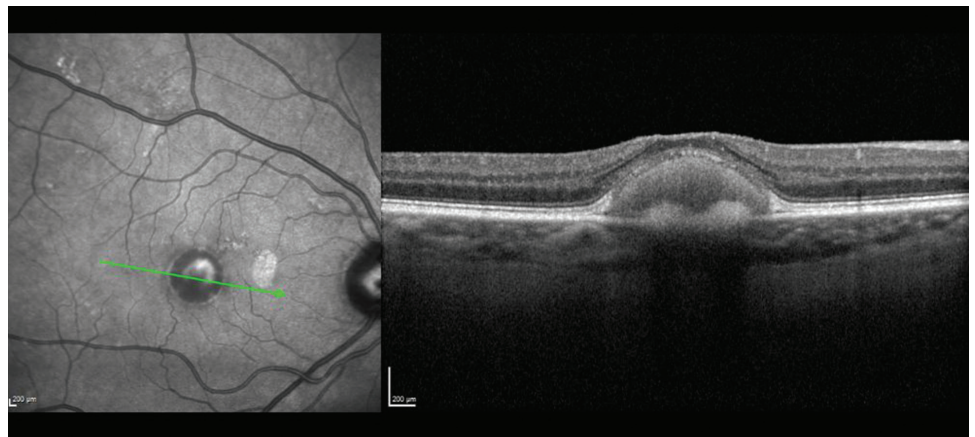


Figure 2 An infrared image (left) demonstrates the central vitelliform deposit seen in Figure 1. An optical coherence tomography (OCT) scan (right) demonstrates the vitelliform material and some thinning of the overlying outer retinal layers. The size of the deposit can be measured and tracked over time. (Photo courtesy of K. Bailey Freund, MD)

continued next page

Acquired Vitelliform Lesions continued from previous page

- Vision for patients with AVLS can vary widely, but nearly half of patients will start with and maintain vision good enough for driving (20/40 or better).
- The size of the lesions can be measured using **optical coherence tomography** (OCT), an imaging technique. Larger lesions (both in width and height) are associated with decreased vision. OCT can also be used to assess the outer retina by evaluating the integrity of its reflective layers.

Diagnostic Testing:

- A complete dilated funduscopic exam is the first step in the diagnosis of adult-onset vitelliform maculopathy. OCT is an important next step and should be repeated over time by a retinal specialist who can monitor any changes in lesion size or outer retinal integrity. (Figure 2)
- **Fluorescein angiography (FA)**, in which a fluorescent intravenous dye is used to provide information about the integrity of retinal blood vessels and to look for signs of a possible complication of this disorder, *choroidal neovascularization* (the formation of new, but defective blood vessels), can also be helpful. **Indocyanine green angiography (ICGA)** or OCT angiography, are sometimes also used to look for choroidal neovascularization.
- Given the association between vitelliform lesions and some genetic disorders, a careful history, electrophysiologic studies, and genetic testing are sometimes indicated to help exclude the possibility of a genetic disorder leading to the eye findings.

Treatment and Prognosis: It is important to differentiate AVLS from neovascular AMD, as AVLS do not require treatment with injections of anti-vascular endothelial growth factor (anti-VEGF) therapy, while neovascular AMD often does. Making this distinction can help avoid unnecessary interventions and risk associated with intravitreal treatment

- Some AVLS may resolve on their own. When they do, the resolution is often associated with *atrophy*, which can result in decreased central vision.
- Adult-onset vitelliform maculopathy does not affect peripheral vision. ●

Clinical Terms (appearing green within fact sheet text)

Fluorescein angiography (FA): An imaging technique where a yellow dye called *sodium fluorescein* is injected into a vein in the arm, allowing a special camera to record circulation in the retina and *choroid* in the back of the eye. This test can be very useful in diagnosing a number of retinal disorders.

Indocyanine green angiography (ICGA): A diagnostic procedure that uses a green dye to illuminate blood flow in the choroid, which is a layer of blood vessels located between the white of the eye (sclera) and the retina that supplies nutrients to the inner eye.

Optical coherence tomography (OCT): A non-invasive imaging technique that uses light to create a 3-dimensional image of your eye for physician evaluation.

Photoreceptors: The light sensing cells found in the outer retina known as the rods (important for night vision) and cones (important for color vision during the day).

Retinal pigment epithelium (RPE): A pigmented layer of the retina lying just outside the retinal photoreceptors, which are the cells that transmit light to the brain.

THANK YOU TO THE RETINA HEALTH SERIES AUTHORS

Sophie J. Bakri, MD
Audina Berrocal, MD
Antonio Capone, Jr., MD
Netan Choudhry, MD, FRCS-C
Thomas Ciulla, MD, MBA
Pravin U. Dugel, MD
Geoffrey G. Emerson, MD, PhD
K. Bailey Freund, MD
Roger A. Goldberg, MD, MBA
Darin R. Goldman, MD
Dilraj Grewal, MD
Larry Halperin, MD
Vi S. Hau, MD, PhD
Suber S. Huang, MD, MBA
G. Baker Hubbard, MD
Mark S. Humayun, MD, PhD
Talia R. Kaden, MD
Peter K. Kaiser, MD
M. Ali Khan, MD
Anat Loewenstein, MD
Mathew J. MacCumber, MD, PhD
Maya Maloney, MD
Hossein Nazari, MD
Oded Ohana, MD, MBA
George Parlitsis, MD
Jonathan L. Prenner, MD
Gilad Rabina, MD
Carl D. Regillo, MD, FACS
Naryan Sabherwal, MD
Sherveen Salek, MD
Andrew P. Schachat, MD
Michael Seider, MD
Janet S. Sunness, MD
Eduardo Uchiyama, MD
Allen Z. Verne, MD
Christina Y. Weng, MD, MBA
Yoshihiro Yonekawa, MD

EDITOR

John T. Thompson, MD

MEDICAL ILLUSTRATOR

Tim Hengst