

Uveal Melanoma Update

Dr. Peter Hovland



Financial Disclosures

I have no relevant financial relationships to disclose



The content and format of this course is presented without commercial bias and does not claim superiority of any commercial product or service.

All relevant financial relationships have been mitigated.

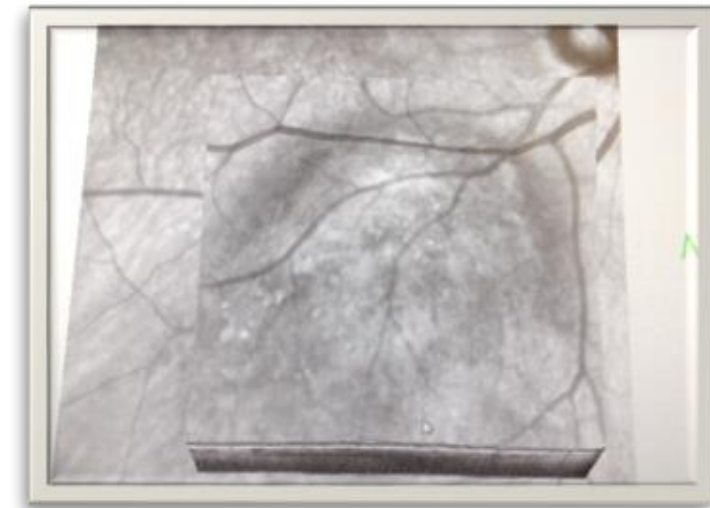
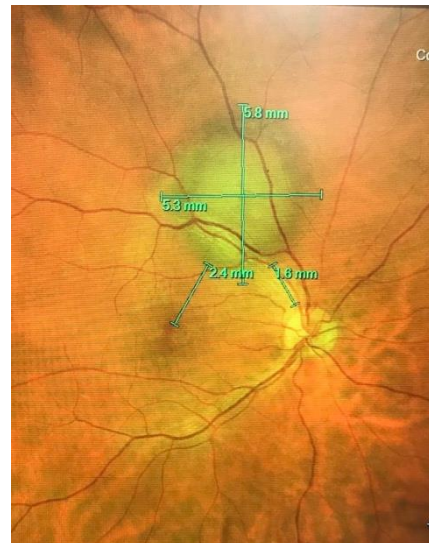
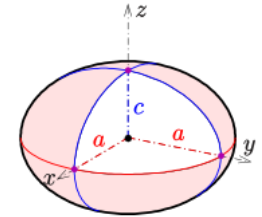
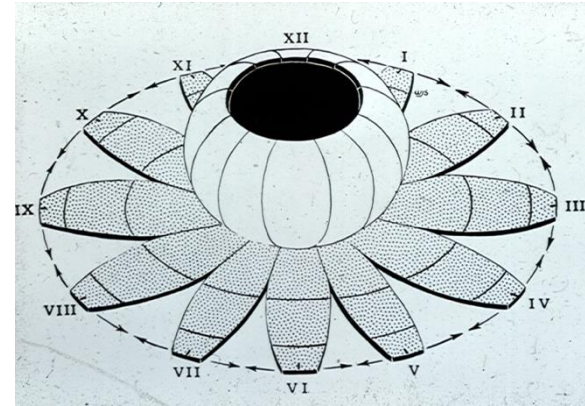
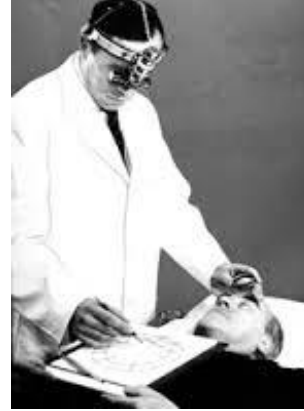Diagnostics

- Detection
- Description
 - Location
 - Proximity to internal eye structures
 - Shape
 - Color
 - Size
 - Measured, estimates of size



Description of Intraocular Lesion

- Quantitative
 - Thickness, diameters (x,y,z)
 - Location
 - Clock hour
 - Anterior-posterior localization
- Qualitative
 - Involvement of eye structures
 - Optic nerve
 - Ciliary Body
 - Appearance
 - Color
 - Shape
- Local tissue effect
 - RPE disruption
 - Subretinal fluid



Differential Diagnosis

- Benign

- Nevus
- “Eccentric Disciform”
- PEHCR
- “Vasoproliferative Tumor” (VPT)
- CHRPE
- Vortex Vein Varix
- Idiopathic Choroidal Scleral Calcification
- Hemangioma
- Osteoma
- Melanocytoma
- Glioma
- Hamartoma of RPE and Retina

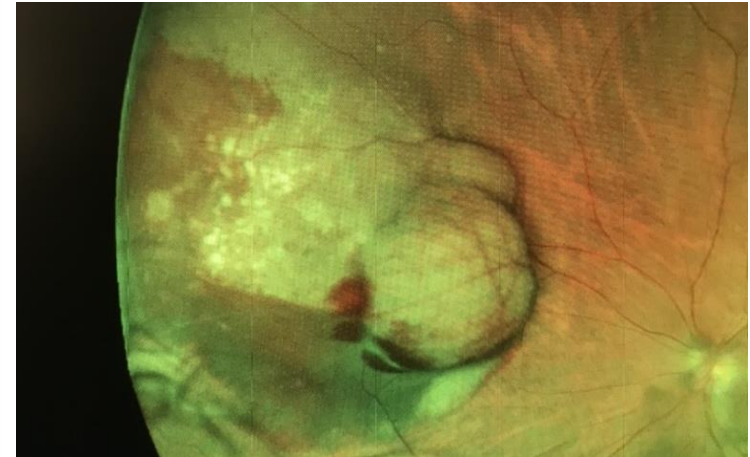
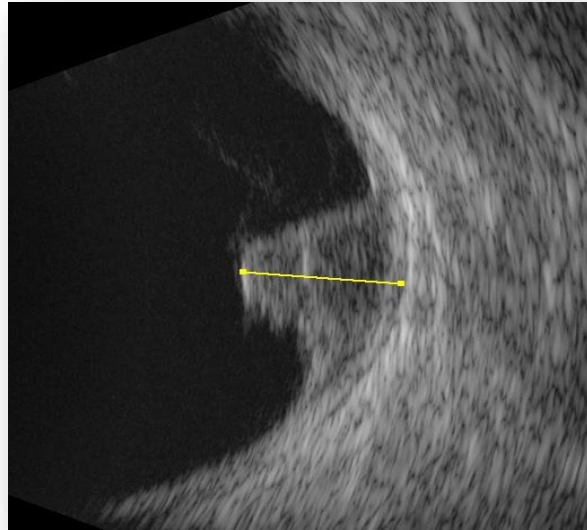


- Malignant

- Melanoma
- Metastasis

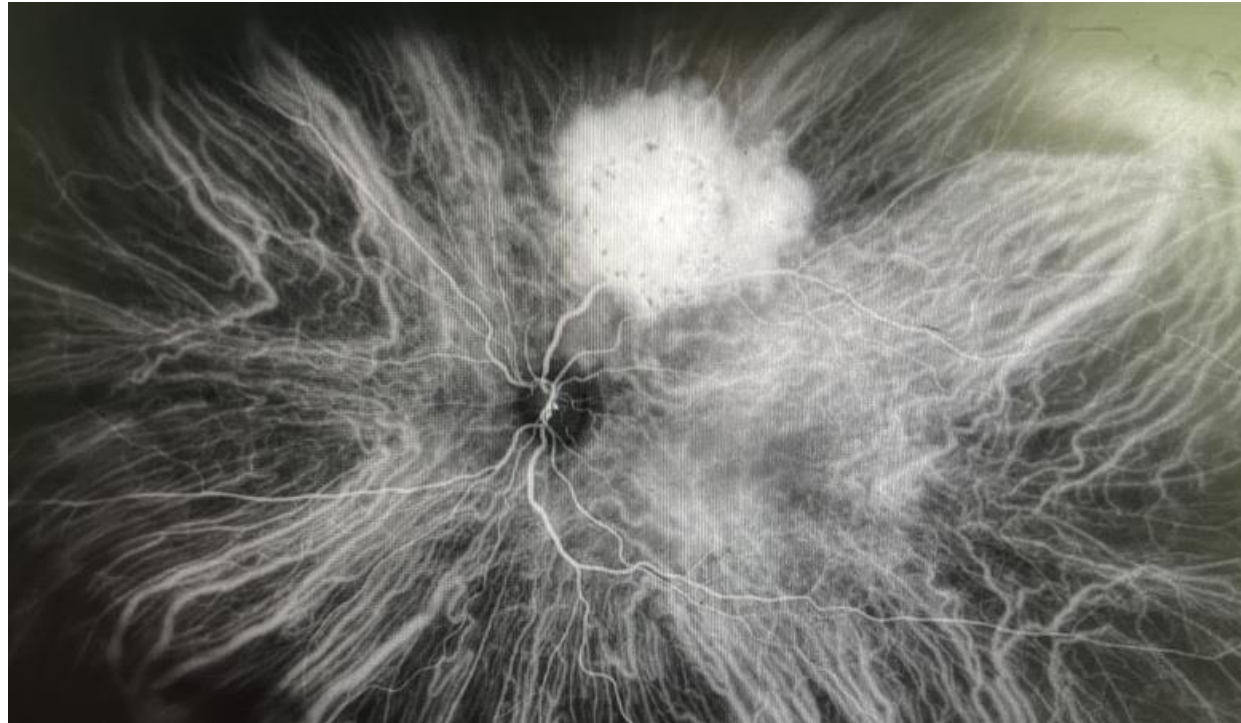
Diagnostic Multimodal Imaging

- Ultrasound
 - Internal reflectivity
 - Associated
 - sRD
 - Hemorrhage



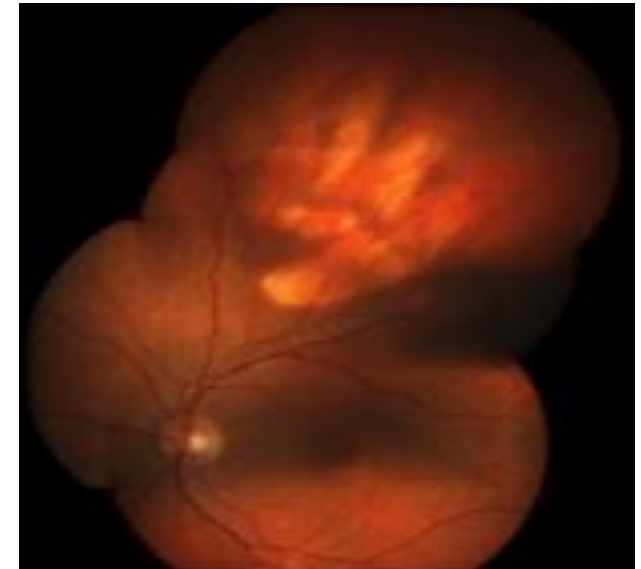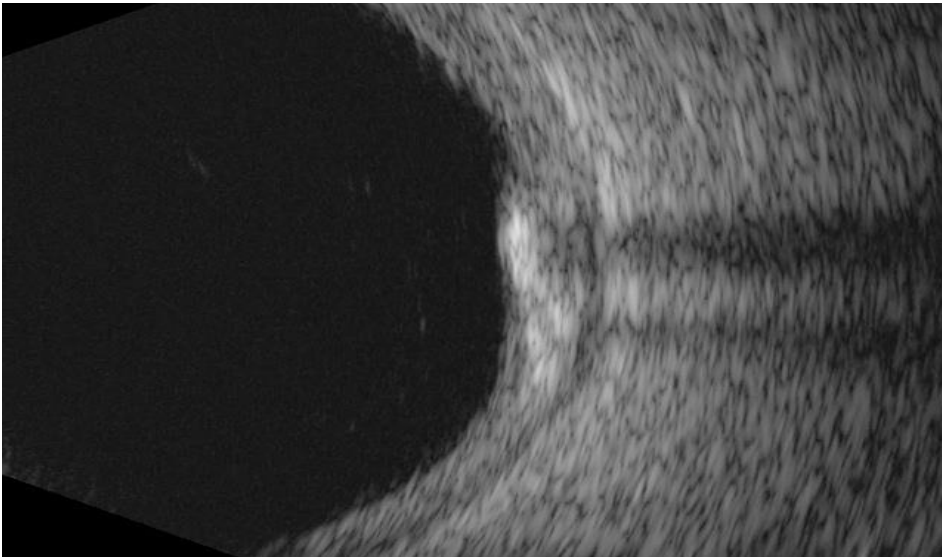
Diagnostic Multimodal Imaging: ICG

- ICG angiography detects choroidal hemangioma



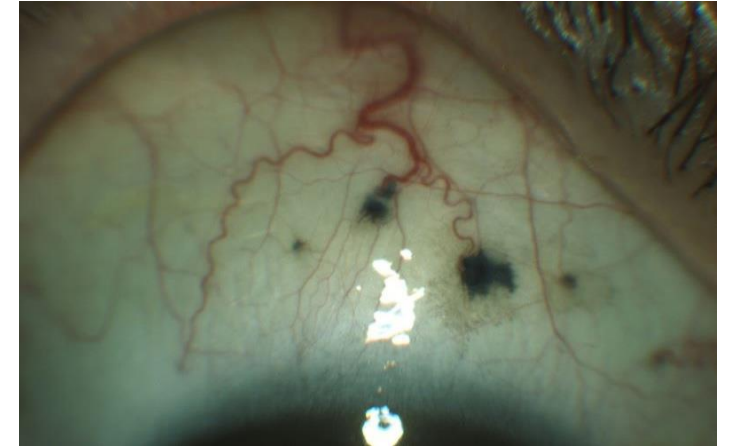
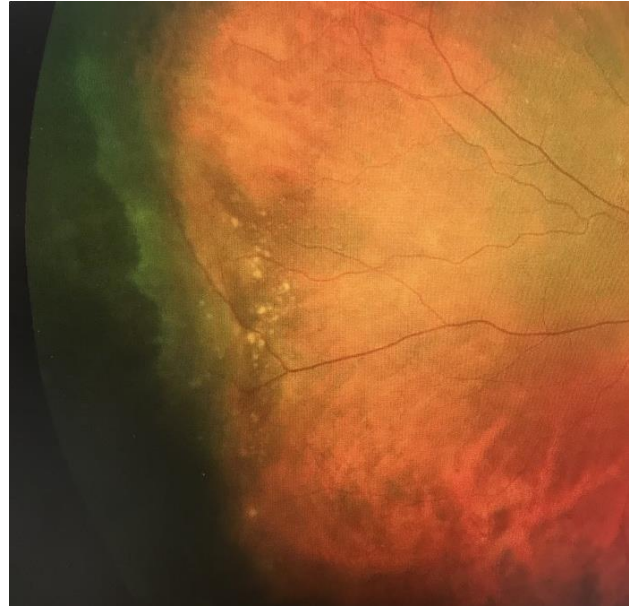
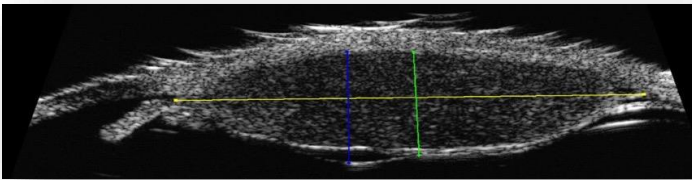
Diagnostic Multimodal Imaging: Ultrasound

- Ultrasound confirms idiopathic choroidal-scleral calcification



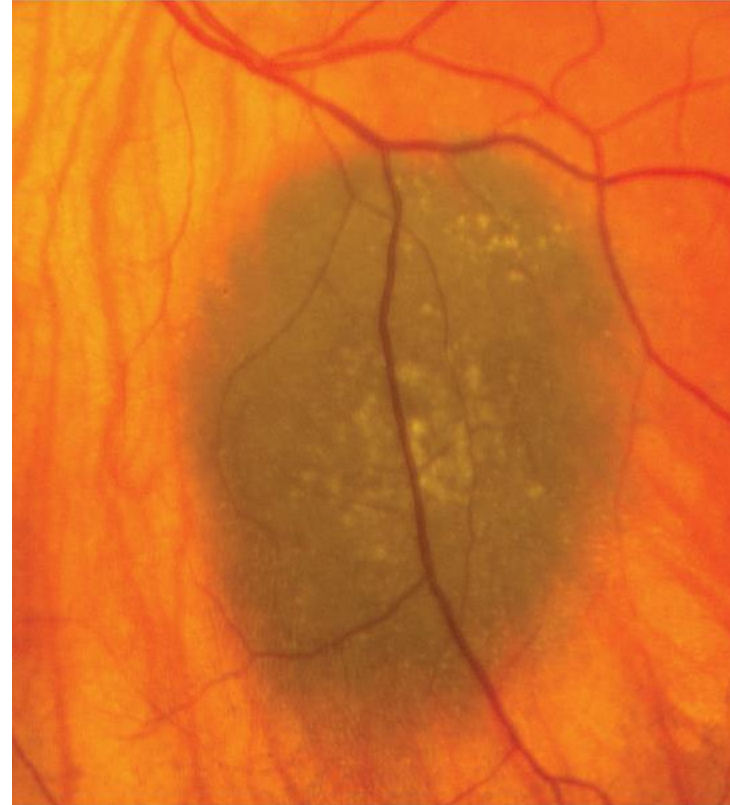Diagnostic Multimodal Imaging: Ultrasound

- Anterior Segment ultrasound confirms ciliochoroidal melanoma

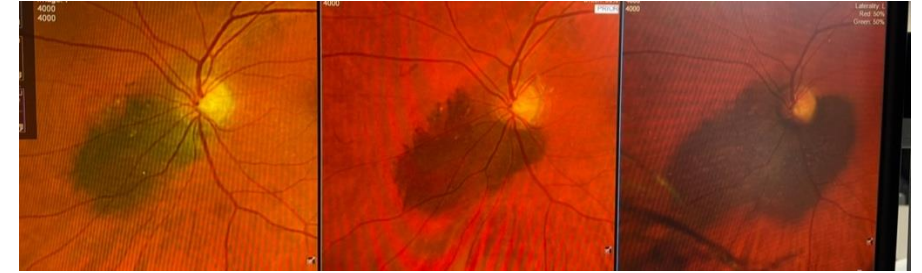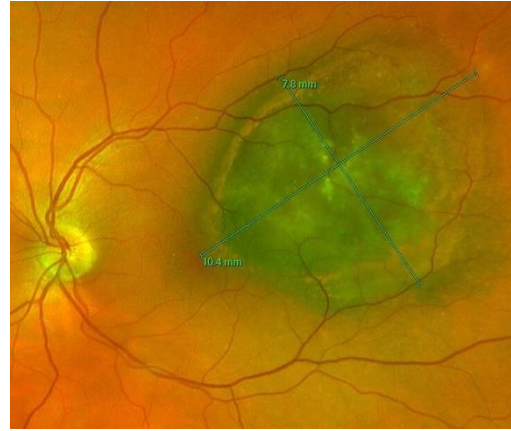


Nevus v. Melanoma

- Nevus characteristics
 - Drusen
 - Gradual central changes
 - RPE metaplasia
 - Atrophy fibrosis
 - SRF at apex
 - CNV - rare

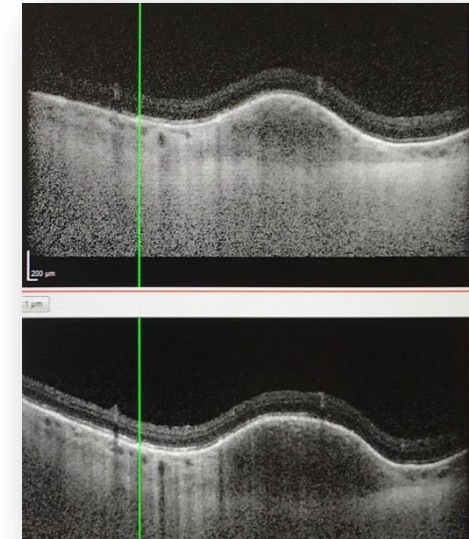
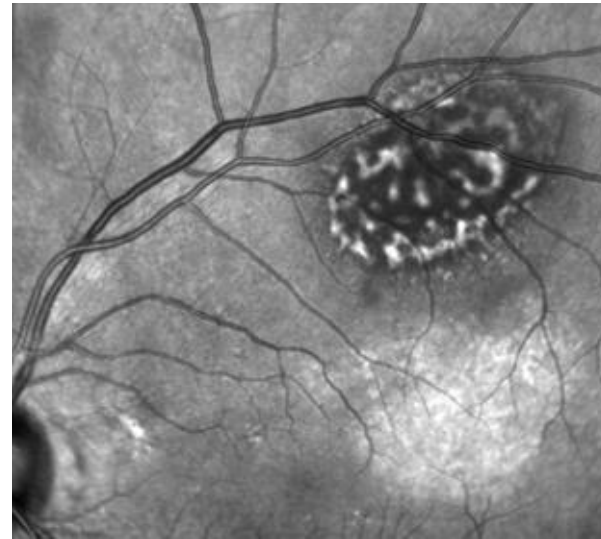


Nevus v. Melanoma



• Melanoma characteristics

- Subretinal fluid
- Orange pigment
- FAF leopard pattern
- Growth
- Symptoms



Incidence of Uveal Melanoma

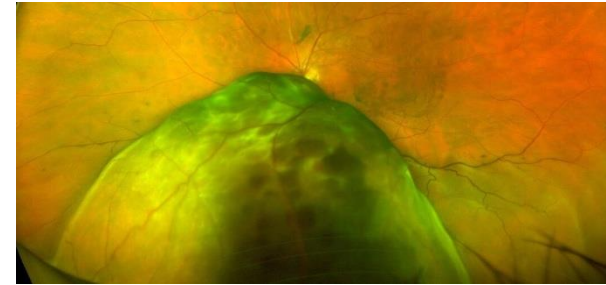
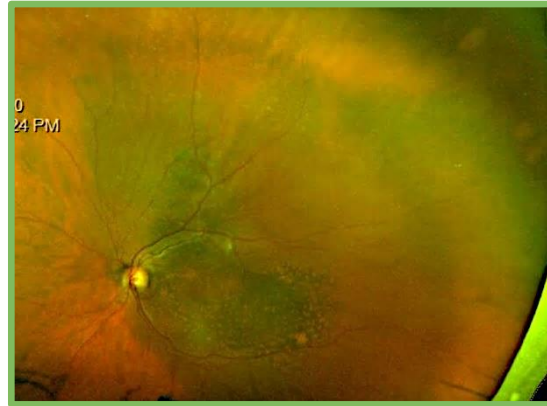- Caucasians
 - 5 per million
- Blue eyes
 - 50%
- Latitude association
 - Higher incidence in Scandinavia
 - 12 per million



Prognosis: Melanoma mortality (50%)

- Anatomic

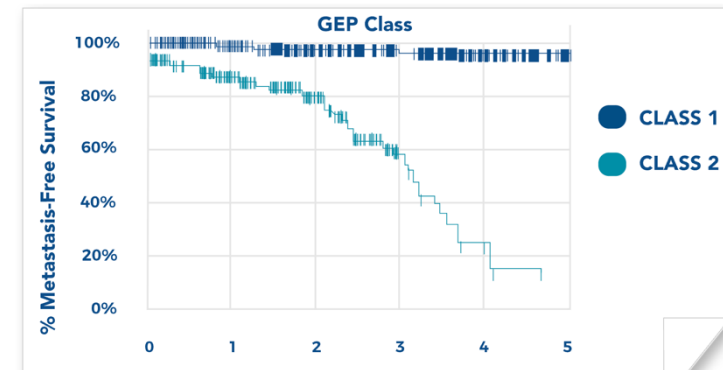
- Tumor Size
 - LBD, thickness
- Location
 - Ciliary body high risk
 - Iris low risk



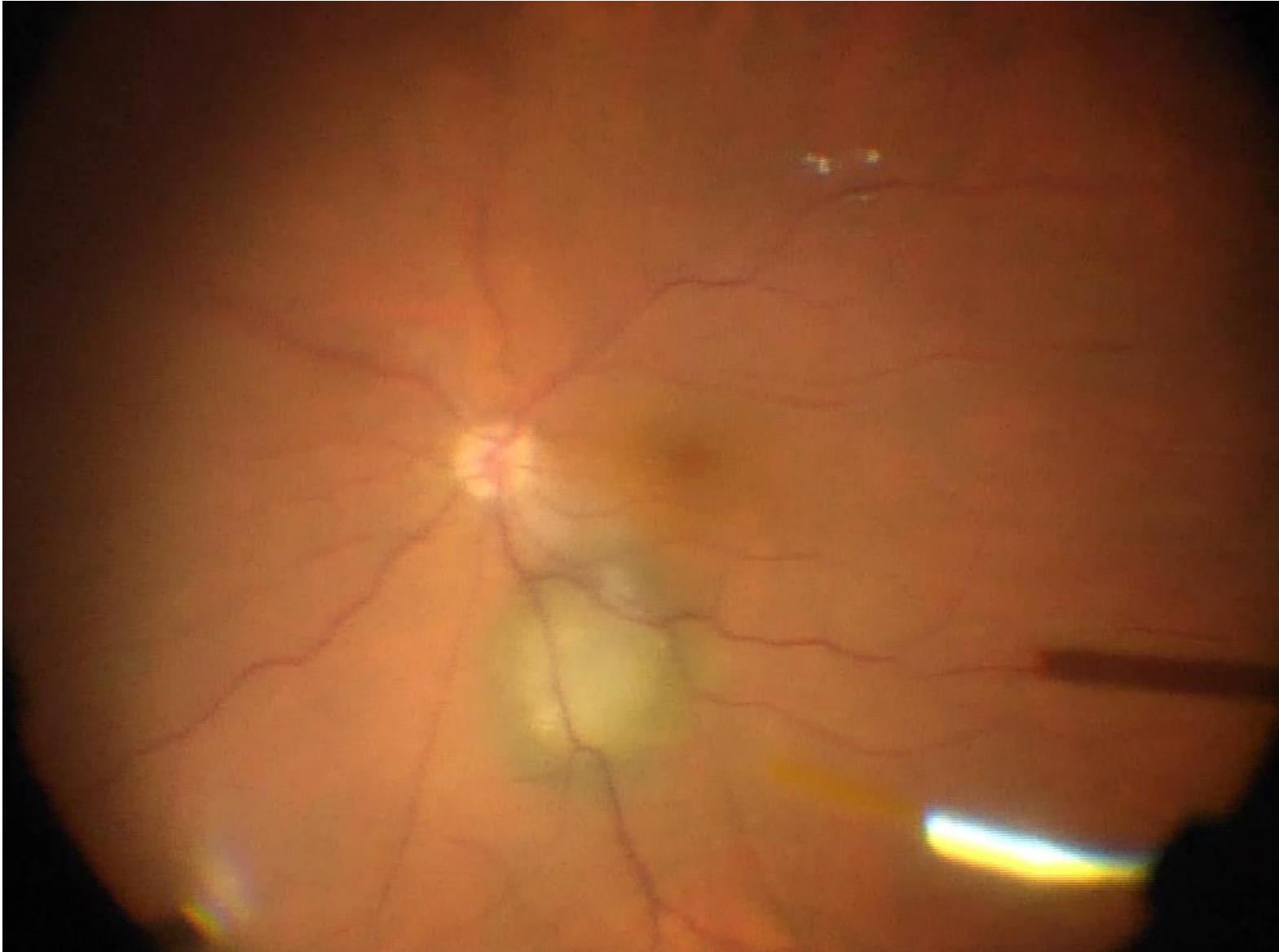- Molecular Markers (GEP, PRAME)

- Low Risk
- High Risk Risk

Metastasis-Free Survival (Onken et al, 2012)



FNAB of small melanoma with 41 g cannula

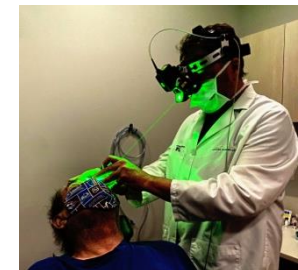
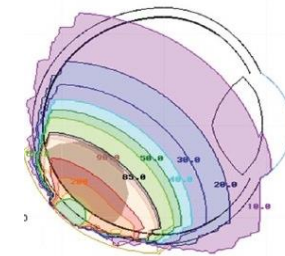
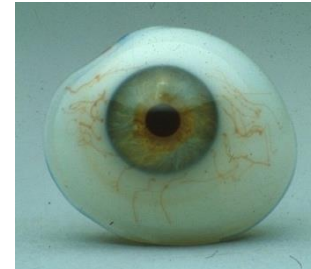

- Careful insertion of cannula through port
- Excellent visualization needed
 - Instrument shadow helpful to detect end
- Once inserted instrument rotated and pulsed
- Material seen within translucent lumen
- Handed off to experienced tech

Melanoma Treatment

- Priorities
 - Life
 - Quality of life
 - Globe salvation
 - Vision

- Large
 - Enucleation
- Medium
 - Radiation
- Small
 - Laser



Confronting Mortality

- Does knowledge of increased probability of near-term mortality impact quality of life?
 - Lead time bias
 - Existential questions
 - Greater appreciation of the moment
- High risk patients enroll in trials



The Seventh Seal” by Ingmar Bergen

A knight plays chess with Death

